This work is licensed under a Creative Commons Attribution-NonCommercial 4.0 International License (CC BY-NC 4.0). To view a copy of the license, visit https://creativecommons.org/licenses/by-nc/4.0/

Traumatic viscerothorax mimicking giant lung bullae

Eurasian Clinical and Analytical Medicine Original Image

Traumatic viscerothorax

Muhammet Sayan[1], Ali Çelik[2]
[1] Department of Thoracic Surgery, Aksaray State Hospital, Aksaray, Türkiye.
[2] Department of Thoracic Surgery, Faculty of Medicine, Gazi University, Ankara, Türkiye.

A 60-year-old man was admitted to the emergency clinic with complaints of palpitations and dyspnea. His past medical history included a car accident and pelvic fracture. Chest X-ray revealed a suspicious large lung bulla, prompting a chest computed tomography (CT) scan. The CT scan demonstrated a complete viscerothorax (Figure 1). A nasogastric tube was inserted, and the operating room was prepared; however, the patient declined surgical intervention.

Traumatic viscerothorax is the migration of abdominal viscera, particularly the stomach and colon, into the thoracic cavity through a ruptured diaphragm.[1] Clinical and radiological findings of viscerothorax can mimic giant lung bullae. Therefore, viscerothorax should be considered in the differential diagnosis of giant lung bullae, as the management strategies for these conditions differ significantly. Viscerothorax constitutes a surgical emergency, and emergency surgery is required following nasogastric tube placement.[2]

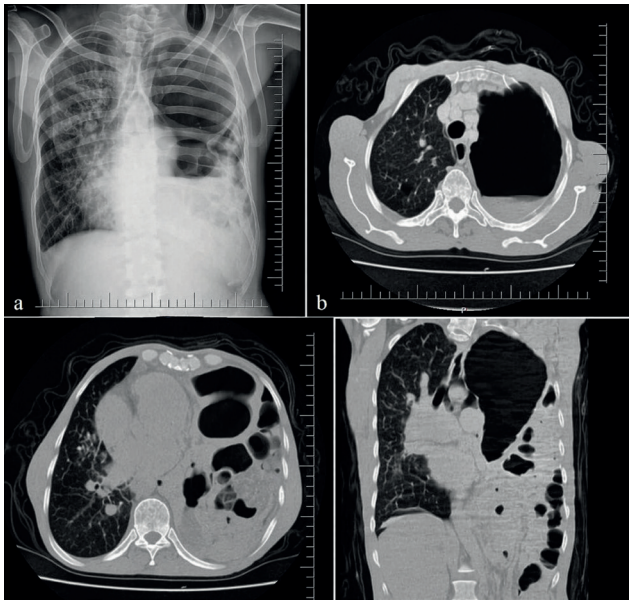

Figure 1. Free air space on left side and contralaterally mediastinal shift (This view resembles a left side giant lung bullae)(a). Air-fluid level on left hemithorax as like a fluid containing giant lung bullae (b). Totally herniation of abdominal viscera to the left chest cavity (c, d).

Declarations

Animal and Human Rights Statement

All procedures performed in this study were in accordance with the ethical standards of the institutional and/or national research committee and with the 1964 Helsinki Declaration and its later amendments.

Informed Consent

Informed consent was obtained from all participants.

Conflict of Interest

The authors declare that there is no conflict of interest.

Funding

None.

Scientific Responsibility Statement

The authors declare that they are responsible for the scientific content of the article, including the study design, data collection, analysis and interpretation, manuscript preparation, and approval of the final version of the manuscript.

References

1. McCann B, O'Gara A. Tension viscerothorax: an important differential for tension pneumothorax. Emerg Med J. 2005;22(3):220-221. doi:10.1136/emj.2003.008367
2. Ahn S, Kim W, Sohn CH, Seo DW. Tension viscerothorax after blunt abdominal trauma: a case report and review of the literature. J Emerg Med. 2012;43(6):451-453.

DOI:10.4328/ECAM.47
Received : 09.01.2015
Accepted : 21.01.2015
Published Online : 22.01.2015
Printed Online : 01.05.2015
Eu Clin Anal Med 2015;3(2). doi:10.4328/ECAM.47

Corresponding Author: Muhammet Sayan, Aksaray State Hospital, Nevsehir Street, Number:110, Postal Code:68200, Aksaray, Türkiye.
P.: +90 382 213 10 43 · **E-Mail:** drsayann@yahoo.com

How to cite this article: Muhammet Sayan, Ali Çelik. Traumatic viscerothorax mimicking giant lung bullae. Eu Clin Anal Med 2015;3(2). doi:10.4328/ECAM.47